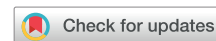

Interpretation of Medical Findings in Suspected Child Sexual Abuse: An Update for 2018



Joyce A. Adams MD^{1,*}, Karen J. Farst MD², Nancy D. Kellogg MD³

¹ Department of Pediatrics, University of California, San Diego School of Medicine, La Jolla, California (retired)

² Department of Pediatrics, University of Arkansas for Medical Sciences, Little Rock, Arkansas

³ Department of Pediatrics, Division of Child Abuse, University of Texas Health Science Center, San Antonio, Texas

ABSTRACT

Most sexually abused children will not have signs of genital or anal injury, especially when examined nonacutely. A recent study reported that only 2.2% (26 of 1160) of sexually abused girls examined nonacutely had diagnostic physical findings, whereas among those examined acutely, the prevalence of injuries was 21.4% (73 of 340). It is important for health care professionals who examine children who might have been sexually abused to be able to recognize and interpret any physical signs or laboratory results that might be found. In this review we summarize new data and recommendations concerning documentation of medical examinations, testing for sexually transmitted infections, interpretation of lesions caused by human papillomavirus and herpes simplex virus in children, and interpretation of physical examination findings. Updates to a table listing an approach to the interpretation of medical findings is presented, and reasons for changes are discussed.

Key Words: Child sexual abuse, Sexually transmitted diseases, Medical findings

Introduction

Most sexually abused children will not have signs of genital or anal injury, especially when examined nonacutely. A recent study reported that only 2.2% (26 of 1160) of sexually abused girls examined nonacutely had diagnostic physical findings, whereas among those examined acutely, the prevalence of injuries was 21.4% (73 of 340).¹

A group of 10 specialists in child abuse pediatrics met over several years to review research studies and recommendations from professional organizations regarding guidelines for providing medical care for children suspected of having been sexually abused. With the support of the Midwest Children's Advocacy Center, guidelines were updated and published in 2016.² Since that time, a few additional studies have been published that provided additional guidance, and parts of the guidelines, including a table listing an approach to the interpretation of medical findings in child sexual abuse have been updated again. In this review we present and discuss new research studies that have informed the recommendations presented herein.

Documentation

In addition to standard documentation of the medical evaluation, the recommended standard of care for children with suspected sexual abuse includes obtaining and preserving high-quality images of the child's medical

examination findings.² Photographs or video recordings can be taken with a camera attached to a colposcope (for magnification), a 35-mm camera with a macro lens, or a digital camera/camcorder capable of high resolution images with or without magnification. Video recordings have the advantage of documenting sections of the examination in a dynamic state. Some clinicians find still photographs more convenient to review when providing a second or expert opinion regarding the presence or absence of abnormal genital or anal findings. With still photos, however, multiple images taken using different methods and examination techniques are needed for the reviewer to completely and accurately assess the examination findings.

One of the more challenging findings to identify and confirm is a transection of the hymen. [Figures 1 and 2](#) show a healed transection in an adolescent patient (item 37, [Table 1](#)); the cotton swab confirms absence of hymen from 6-8 o'clock. A recent study³ compared agreement between survey participants and the examiner from the study center regarding the presence of a hymen transection, using video recordings taken during a sexual abuse medical evaluation. The video records selected were from 8 adolescent sexual abuse nonacute genital examinations. The cases were chosen retrospectively, with 3 showing a hymen deep notch and 5 showing a hymen transection. Survey participants were asked to decide whether or not a transection was documented in the still images or videos from the case, first viewing 4 still images captured from the video of each case, followed, in a random order, by the video clip edited to show the finding in question.

The results showed that agreement with the study center diagnosis was significantly better ($P < .01$) when video vs still photos of an examination were viewed. There were 2

The authors indicate no conflicts of interest.

* Address correspondence to: Joyce A. Adams, MD, 401 Florin Rd, Sacramento, CA.
E-mail address: jadams@ucsd.edu (J.A. Adams).

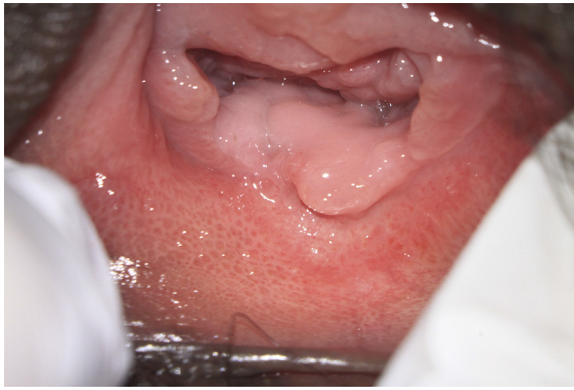


Fig. 1. This photograph shows the vestibule, hymen, and fossa of an adolescent girl, using labial separation. There appears to be a loss of hymen tissue between 6 and 9 o'clock, with visualization of the vaginal floor. Additional examination techniques are required to confirm the finding.

cases in which the diagnosis changed after the videos were presented from “no transection” to “transection.” The authors comment on the importance of correctly identifying a hymen transection, because that is the only nonacute hymen finding that is considered clear evidence of past injury. Thus, video recordings might document the examination findings more clearly, an advantage for obtaining second opinions on whether or not the examination shows signs of injury.

Photo documentation of all examinations has many advantages. Regular review of examination findings with a provider with expertise in child sexual abuse provides an opportunity for team members to learn from more experienced examiners about the variable appearance of normal genital and anal anatomic features. For example, a groove in the mid fossa (Fig. 3; item 9a in Table 1) is a normal midline anatomic feature typically seen in pubertal female adolescents. The appearance of the hymenal rim might change with examination position or technique; Figures 4 and 5

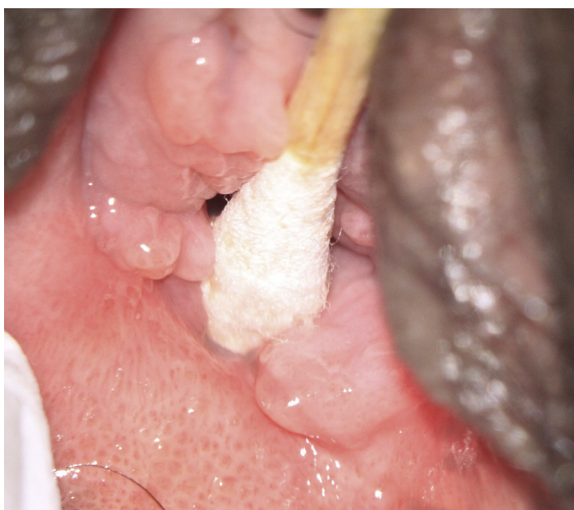

Fig. 2. This is the same patient as shown in Fig. 1. A cotton swab is being used to demonstrate the absence of hymen between 6 and 8 o'clock, confirming the presence of a hymen transection. This finding is considered to be a definitive sign of past injury to the hymen, which was torn through to the base of the hymen.

show an annular hymen (item 1a, Table 1) in a prepubertal girl with a thinner, but normal appearing hymenal rim in prone knee-chest position (item 1k, Table 1). Via expert review of these photographs, less experienced clinicians who might be concerned about the appearance of the hymenal rim will become more familiar with variations in normal anogenital anatomy. Quality improvement programs could also focus on improvement in photographic images, examination technique for better visualization of tissues, and recognition of findings unrelated to trauma or sexual contact.

Testing for Sexually Transmitted Infections

In prepubertal children, the prevalence of sexually transmitted infections (STIs) among girls examined for possible sexual abuse is low; 6.7% for chlamydia and 1.8% for *Neisseria gonorrhea* in 1 recent study.⁴ The American Academy of Pediatrics' Committee on Child Abuse and Neglect⁵ suggests that STI testing in prepubertal children be considered when:

- (1) Child has experienced penetration of the vagina or anus
- (2) Child has been abused by a stranger
- (3) Child has been abused by a perpetrator known to be infected with an STI or is at high risk for being infected (intravenous drug users, men who have sex with men, or people with multiple sexual encounters)
- (4) Child has a sibling or other relative in the household with an STI
- (5) Child lives in an area with a high rate of STI in the community
- (6) Child has signs or symptoms of an STI
- (7) Child has already been diagnosed with one STI

Because of the ease of collection and possibility of asymptomatic infection, some centers obtain urine samples for nucleic acid amplification (NAAT) testing for *N. gonorrhea* and *Chlamydia trachomatis* from all children evaluated for sexual abuse. When using this approach, the cost of such screening tests should be taken into consideration.

The Centers for Disease Control and Prevention (CDC)⁶ has determined that for prepubertal girls, a urine or vaginal swab sample for NAAT *N. gonorrhea* and chlamydia trachomatis can replace vaginal culture for both organisms. In the study by Leder et al,⁴ Aptima Combo 2 (AC2; Hologic, Inc) tests for gonorrhea as well as chlamydia were significantly more sensitive than culture. In the case of chlamydia, 28 girls had positive urine or vaginal samples positive using AC2, but cultures for chlamydia were positive in only 7 girls (26% sensitivity). Vaginal swabs were slightly less sensitive (90%) than urine (100%) in detecting chlamydia, using AC2 testing. For gonorrhea, using AC2 testing, the vaginal swab sample detected 1 additional case (n = 8), compared with the urine NAAT (n = 7), but gonorrhea culture was positive in only 3 of the 8 cases (38% sensitivity). These data suggest that it is not only acceptable to use NAAT testing on vaginal swabs or urine samples to detect genital infections by gonorrhea and chlamydia in prepubertal girls, but that NAAT testing might be preferable to vaginal cultures.

Table 1

2018 Updated Approach to Interpretation of Medical Findings in Suspected Child Sexual Abuse

Section 1. Physical findings

A. Findings documented in newborns or commonly seen in nonabused children. These findings are normal and are unrelated to a child's disclosure of sexual abuse

Normal variants

1. Normal variations in appearance of the hymen
 - a. Annular: hymenal tissue present all around the vaginal opening including at the 12 o'clock location
 - b. Crescentic hymen: hymenal tissue is absent at some point above the 3–9 o'clock locations
 - c. Imperforate hymen: hymen with no opening
 - d. Microperforate hymen: hymen with 1 or more small openings
 - e. Septate hymen: hymen with 1 or more septae across the opening
 - f. Redundant hymen: hymen with multiple flaps, folding over each other
 - g. Hymen with tag of tissue on the rim
 - h. Hymen with mounds or bumps on the rim at any location
 - i. Any notch or cleft of the hymen (regardless of depth) above the 3 and 9 o'clock location
 - j. A notch or cleft in the hymen, at or below the 3 o'clock or 9 o'clock location, that does not extend nearly to the base of the hymen
 - k. Smooth posterior rim of the hymen that appears to be relatively narrow along the entire rim; might give the appearance of an "enlarged" vaginal opening
2. Periurethral or vestibular band(s)
3. Intravaginal ridge(s) or column(s)
4. External ridge on the hymen
5. Diastasis ani (smooth area)
6. Perianal skin tag(s)
7. Hyperpigmentation of the skin of labia minora or perianal tissues in children of color
8. Dilation of the urethral opening
9. Normal midline anatomic features
 - a. Groove in the fossa, seen in early adolescence
 - b. Failure of midline fusion (also called perineal groove)
 - c. Median raphe (has been mistaken for a scar)
 - d. Linea vestibularis (midline avascular area)
10. Visualization of the pectinate/dentate line at the juncture of the anoderm and rectal mucosa, seen when the anus is fully dilated
11. Partial dilatation of the external anal sphincter, with the internal sphincter closed, causing visualization of some of the anal mucosa beyond the pectinate line, which might be mistaken for anal laceration

B. Findings commonly caused by medical conditions other than trauma or sexual contact. These findings require that a differential diagnosis be considered, because each might have several different causes

12. Erythema of the anal or genital tissues
 13. Increased vascularity of vestibule and hymen
 14. Labial adhesion
 15. Friability of the posterior fourchette
 16. Vaginal discharge that is not associated with a sexually transmitted infection
 17. Anal fissures
 18. Venous congestion or venous pooling in the perianal area
 19. Anal dilatation in children with predisposing conditions, such as current symptoms or history of constipation and/or encopresis, or children who are sedated, under anesthesia, or with impaired neuromuscular tone for other reasons, such as postmortem
- C. Findings due to other conditions, which can be mistaken for abuse
20. Urethral prolapse
 21. Lichen sclerosus et atrophicus
 22. Vulvar ulcer(s), such as aphthous ulcers or those seen in Behcet disease
 23. Erythema, inflammation, and fissuring of the perianal or vulvar tissues due to infection with bacteria, fungus, viruses, parasites, or other infections that are not sexually transmitted
 24. Rectal prolapse
 25. Red/purple discoloration of the genital structures (including the hymen) from lividity postmortem, if confirmed by histological analysis

D. No expert consensus regarding degree of significance. These physical findings have been associated with a history of sexual abuse in some studies, but at present, there is no expert consensus as to how much weight they should be given, with respect to abuse.

Findings 27 and 28 should be confirmed using additional examination positions and/or techniques, to ensure they are not normal variants (findings 1.i, 1.j) or a finding of residual traumatic injury (finding 37)

26. Complete anal dilatation with relaxation of the internal as well as external anal sphincters, in the absence of other predisposing factors such as

constipation, encopresis, sedation, anesthesia, and neuromuscular conditions

27. Notch or cleft in the hymen rim, at or below the 3 o'clock or 9 o'clock location, which extends nearly to the base of the hymen, but is not a complete transection. This is a very rare finding that should be interpreted with caution unless an acute injury was documented at the same location
28. Complete cleft/suspected transection to the base of the hymen at the 3 or 9 o'clock location

E. Findings caused by trauma. These findings are highly suggestive of abuse, even in the absence of a disclosure from the child, unless the child and/or caretaker provides a timely and plausible description of accidental anogenital straddle, crush or impalement injury, or past surgical interventions that are confirmed from review of medical records. Findings that might represent residual/healing injuries should be confirmed using additional examination positions and/or techniques

1) Acute trauma to genital/anal tissues

29. Acute laceration(s) or bruising of labia, penis, scrotum, or perineum
 30. Acute laceration of the posterior fourchette or vestibule, not involving the hymen
 31. Bruising, petechiae, or abrasions on the hymen
 32. Acute laceration of the hymen, of any depth; partial or complete
 33. Vaginal laceration
 34. Perianal laceration with exposure of tissues below the dermis
- 2) Residual (healing) injuries to genital/anal tissues
35. Perianal scar (a very rare finding that is difficult to diagnose unless an acute injury was previously documented at the same location)
 36. Scar of posterior fourchette or fossa (a very rare finding that is difficult to diagnose unless an acute injury was previously documented at the same location)
 37. Healed hymenal transection/complete hymen cleft—a defect in the hymen below the 3–9 o'clock location that extends to or through the base of the hymen, with no hymenal tissue discernible at that location
 38. Signs of FGM or cutting, such as loss of part or all of the prepuce (clitoral hood), clitoris, labia minora or labia majora, or vertical linear scar adjacent to the clitoris (type 4 FGM)

Section 2. Infections

A. Infections not related to sexual contact

39. Vaginitis caused by fungal infections such as *Candida albicans*, or bacterial infections transmitted by nonsexual means, such as *Streptococcus* type A or type B, *Staphylococcus* sp, *Escherichia coli*, *Shigella* or other gram-negative organisms
40. Genital ulcers caused by viral infections such as Epstein-Barr virus or other respiratory viruses

B. Infections that can be spread by nonsexual as well as sexual transmission. Interpretation of these infections might require additional information, such as mother's gynecologic history (HPV) or child's history of oral lesions (HSV), or presence of lesions elsewhere on the body (Molluscum) which might clarify likelihood of sexual transmission. After complete assessment, a report to Child Protective Services might be indicated in some cases. Photographs or video recordings of these findings should be taken, then evaluated and confirmed by an expert in sexual abuse evaluation to ensure accurate diagnosis

41. *Molluscum contagiosum* in the genital or anal area. In young children, transmission is most likely nonsexual. Transmission from intimate skin-to-skin contact in the adolescent population has been described
42. Condyloma acuminatum (HPV) in the genital or anal area. Warts appearing for the first time after age 5 years might be more likely to have been transmitted by sexual contact
43. HSV type 1 or 2 infections in the oral, genital, or anal area

C. Infections caused by sexual contact, if confirmed using appropriate testing, and perinatal transmission has been ruled out

44. Genital, rectal, or pharyngeal *Neisseria gonorrhea* infection
45. Syphilis
46. Genital or rectal *Chlamydia trachomatis* infection
47. *Trichomonas vaginalis* infection
48. HIV, if transmission by blood or contaminated needles has been ruled out

Section 3. Findings diagnostic of sexual

49. Pregnancy
50. Semen identified in forensic specimens taken directly from a child's body

FGM, female genital mutilation; HPV, human papillomavirus; HSV, herpes simplex virus.

This table lists medical and laboratory findings; however, most children who are evaluated for suspected sexual abuse will not have physical signs of injury or infection. The child's description of what happened and report of specific symptoms in relationship to the events described are both essential parts of a full medical evaluation.

When a urine or vaginal sample is positive for gonorrhea or chlamydia in a prepubertal child in whom sexual abuse is suspected, the CDC⁶ recommends that the NAAT sample be retained for further testing. Hammerschlag and Gaydos⁷ clarified that in a child, when a NAAT from a urine sample or vaginal swab is positive for gonorrhea or chlamydia, confirmatory testing with a second, alternate target NAAT should be considered. In adolescents and adults, no confirmatory testing is necessary according to the CDC.⁶

A few previous studies of adolescents and adults have reported gonorrhea and chlamydia infections isolated from extragenital sites using NAAT testing.^{8,9} In a recent study¹⁰ of 1319 children and adolescents who presented for acute and nonacute assessments for sexual abuse/assault and were tested for gonorrhea and chlamydia, 120 had at least 1 positive NAAT from a genital or extragenital (oral, anal) site. Most patients who tested positive for gonorrhea or chlamydia did not have genital discharge and most who had positive results from extragenital sites did not provide a history of contact at that site. Fifty-one patients had a positive anal NAAT, with 46 positive for chlamydia, and 24 had a positive oral NAAT, with 16 positive for chlamydia. More than half of the positive tests were in patients who were seen within 96 hours of sexual contact. Results from this study suggest that some of the positive anal NAAT tests might represent contiguous spread or assailant secretions after an acute sexual assault. In addition, these study findings indicate that testing protocols on the basis of patient symptoms or reported type of sexual contact might result in missed gonorrhea or chlamydia infections, particularly involving oral and anal sites.

Recommendations on the use of NAAT for *Trichomonas vaginalis* in child sexual abuse are limited.^{11,12} It likely has the same benefits of increased sensitivity and ease of collection compared with culture and wet-mount specimens in young children, which has been shown in adolescents/adults. Practitioners using NAAT for *T. vaginalis* in cases of suspected child sexual abuse/assault should develop a confirmation strategy to use in cases in which the results could have forensic significance because of low prevalence of infection, which negatively affects the positive predictive value of the result. Alternate sequence NAAT testing for *T. vaginalis* is now possible because additional NAATs have become commercially available.^{11,12} Cost is a current barrier to using NAAT for initial and/or confirmation testing for *T. vaginalis* because this is still an expanding technology. Currently, the CDC⁶ recommends trichomonas culture as the most sensitive test that is readily available. Immunoassays and probe-based hybridizations should not be used for initial or confirmation testing in young children.⁷

Interpretation of Physical and Laboratory Findings

Because it is important to correctly diagnose and interpret medical findings in children who might have been sexually abused, guidelines for medical assessment published in 2016² included a table detailing a suggested approach to interpreting findings as normal, caused by other conditions, and caused by trauma or sexual contact.

To determine the level of agreement among providers of sexual abuse evaluations with the listing of findings in the 2016 guidelines, a survey was conducted. In January of 2017, an invitation to participate was sent via the organization's listserv to the 491 members of the Ray E. Helfer Society, an honorary society for physicians involved in the assessment of child abuse. However, although all members are experts in the evaluation of suspected child abuse or neglect, not all were actively providing medical evaluations for suspected child sexual abuse in their current roles. The survey instructions delineated that it was intended for those currently active in the assessment of child sexual abuse.

There were 97 responses, 90 of which were from physicians who were active in the medical assessment of suspected child sexual abuse. Most (80) were physicians in the United States, but 10 were from other countries, including Canada, Australia, Ireland, Norway, Iceland, and Saudi Arabia. The results of the survey are listed in Table 2.

There was 80%–100% agreement among the survey participants with how the listed findings were interpreted in the updated guidelines.² The only finding with less than 80% agreement was “deep notch in the posterior rim of the hymen” (68%), which was in the “no expert consensus” section of the table. This particular finding was also one that generated the most discussion among the authors of the updated guidelines, who were polled recently about any additional changes that should be made to the table. There was agreement that the table should be rearranged to separate physical findings from infections, and signs of acute injury from signs of healed injury (Table 1).

The heading for the “no expert consensus” section of the table has been modified to reflect the fact that although these physical examination finding could be related to past trauma or sexual abuse, experts do not agree on how much significance should be assigned to the findings, with respect to abuse. The comment that a finding in this section could support a disclosure of abuse from the child, if one is given, has been removed. As always, the details of the disclosure of abuse from the child is the most important part of an evaluation, whether or not a physical or laboratory finding is present.

STIs

The finding of Molluscum contagiosum was moved from the section: “Findings commonly caused by medical conditions other than trauma or sexual abuse” to the new section “Infections that might be caused by sexual or nonsexual contact.” In sexually active adolescents and adults, Molluscum contagiosum is considered by some to be an STI,^{13,14} because it can be spread by intimate skin-to-skin contact during sexual encounters. In children, it is usually spread by fomites or by the child, who scratches one lesion and spreads it to other parts of his or her body.

Condyloma acuminatum, caused by human papillomavirus (HPV) remains in the same section of the table, as an infection that can be spread by sexual or nonsexual contact. This is supported by a new study from Greece,¹⁵ which tested vaginal swab samples for HPV using a NAAT test (CLART HPV 2; Genomica SAU). The study population

included sexually active adolescent girls ($n = 38$), non-sexually active adolescent girls ($n = 28$), and prepubertal girls ($n = 29$), all of whom were presenting for either routine gynecologic care (the sexually active group), or vaginal complaints such as vaginal discharge (the non-sexually active group and the children). The authors state that the exclusion criteria for the study included pregnancy and sexual abuse.

In this study, vaginal samples were positive for HPV in 37.9% of the patients. The prevalence of infection was 47.4% in the sexually active adolescents, 28.6% in the non-sexually active adolescents, and 34.5% in the prepubertal girls. The authors concluded that: “Because HPV genital infection before sexual debut seems to be more common than was previously thought, clinicians should be very careful when suspecting sexual abuse only on the basis of positive HPV testing.” The relationship between a positive clinical test and clinical disease remains to be clarified. This high rate of positive tests in sexually active as well as non-sexually active adolescents and children is an issue worthy of

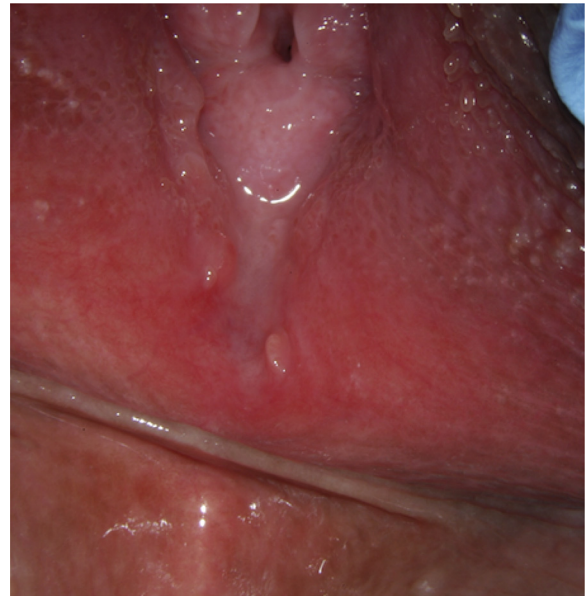

Fig. 3. This photograph of the genital area of a 12-year-old girl shows a shallow groove in the fossa in the midline. This feature is commonly seen in girls in the early stages of pubertal development. The small fleshy protrusions along the sides of the groove are normal vestibular papillae, which should not be mistaken for signs of injury.

Table 2

Results of a Survey on Level of Agreement with the 2016 Interpretation of Findings in Child Sexual Abuse

- 1) Familiar with Adams et al² 2016 Updated Guidelines report: 94% said yes
- 2) Agree with 80% or more of the findings listed in sections of Table 1:
 - a. Normal or normal variants: 94%
 - b. Commonly caused by other conditions: 94%
 - c. Conditions mistaken for abuse: 89%
- 3) Agree with listing of individual findings in other sections?
 - a. No expert consensus
 - i. Complete anal dilation in absence of predisposing factors: 84%
 - ii. Deep hymen notch in posterior hymen rim: 68%
 - iii. Genital or anal condyloma with no other indicators of abuse (first appearing after the age of 5 years): 91%
 - iv. Confirmed HSV-1 or HSV-2 in genital or anal areas in a child with no other indicators of abuse: 83%
 - b. Acute trauma to external genital or anal tissues (could be accidental or inflicted)
 - i. Acute laceration or bruising of the labia, penis, scrotum, perianal tissues, or perineum: 100%
 - ii. Acute laceration of the posterior fourchette or vestibule, not involving the hymen: 99%
 - c. Residual (healing) injuries to the external genital or anal tissues
 - i. Perianal scar: 96%
 - ii. Scar of the posterior fourchette: 96% (several responders commented that these are very rare findings and difficult to interpret unless seen in follow-up after an acute injury at that location that was previously documented)
 - d. Injuries indicative of acute or healed trauma to genital or anal tissues
 - i. Acute laceration of the hymen, of any depth: 98%
 - ii. Vaginal laceration: 100%
 - iii. Healed hymen transection/complete cleft below the 3 or 9 o'clock location: 100%
 - iv. Perianal laceration: 95%
 - v. Petechiae or abrasions to the hymen: 96%
 - e. Infections transmitted by sexual contact (if not due to perinatal transmission or congenital)
 - i. Genital, rectal, or pharyngeal *Neisseria gonorrhea*: 98%
 - ii. Syphilis: 100%
 - iii. Genital or rectal chlamydia (unsure of total, because the chlamydia question was inadvertently left off the survey during the initial posting)
 - iv. *Trichomonas vaginalis* infection: 81%
 - f. Diagnostic of sexual contact
 - i. Pregnancy: 100%
 - ii. Semen identified in forensic specimens taken directly from a child's body: 95%

HSV, herpes simplex virus.

further study because this might result in a lower degree of suspicion of sexual abuse in children and teens with genital warts. Until test result interpretation and management are clarified, an HPV NAAT is of questionable clinical and forensic value in the assessment of children and adolescents for sexual abuse or assault.

Oral, genital, or anal infections caused by herpes simplex virus (HSV) type 1 and type 2 are also listed as infections that can be spread by sexual or nonsexual contact. Young children are more likely to present with HSV type 1 as oral lesions, rather than genital lesions,¹⁶ so the possibility of autoinoculation from an oral lesion must be considered in a child with HSV infection in the genital or anal area. Although HSV type 2 has been considered in the past to be the main cause of genital herpes in women, a more recent epidemiologic study¹⁶ reported that the opposite was true. Among women in the United States aged 18–30, the prevalence of genital HSV type 1 (3.7%) was higher than the prevalence of genital HSV type 2 (1.6%). There were also racial differences in the rates of HSV type 2 infections: 20 of 27 (74%) of the infections in non-Hispanic black women were caused by HSV type 2, compared with 31 of 135 (23%) of infections among non-Hispanic white women, and 4 of 10 (40%) of the infections among Hispanic women.¹⁶

A genital or anal HSV type 2 infection in a child could indicate sexual transmission more than a genital or anal infection due to HSV type 1 because nonsexual autoinoculation with HSV type 2 is not well described. However, because more genital infections in young adult Hispanic and non-Hispanic white women are now primarily caused by HSV type 1,¹⁶ it is clear that serologic typing is not a reliable method for definitively determining mode of transmission. Typing might still be helpful in clinical management because HSV type 2 infections will be more likely to require management for recurrence.

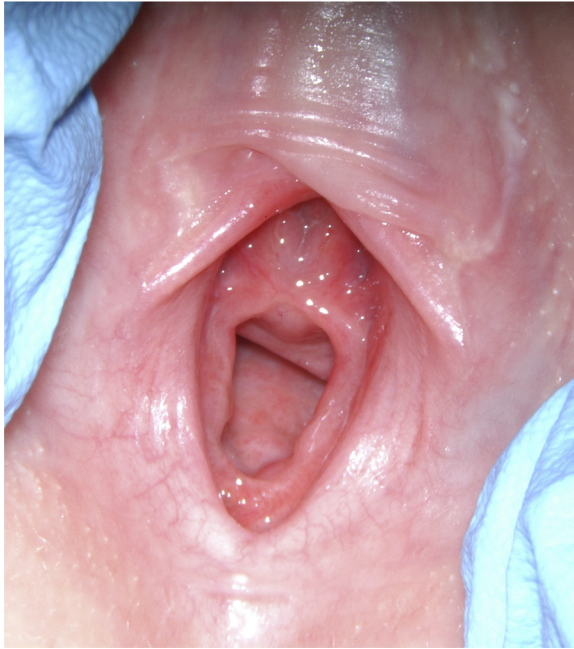

Fig. 4. This photograph shows the genital tissues of a 5-year-old girl examined in the supine position, using labial separation. She was brought for a sexual abuse evaluation several weeks after an event she described as “He put his private in my private, in the front.” There are no signs of acute injury. The labia minora are short, which is typical of the appearance in a prepubertal girl. There is hymen tissue all the way around the hymen opening.

Should the known or suspected offender in the child’s case have serologic testing done for HSV? It is doubtful that such testing would be helpful in most situations. The most commonly used serologic test for type-specific antibodies to HSV is HerpeSelect-2 EIA (Focus Technologies, Cypress, CA). If the child’s genital or anal lesions were caused by HSV type

1, a suspect’s positive antibody test for HSV type 1 would mean very little, because a high percentage of adults will have antibodies to HSV type 1, even if there is no history of them ever having oral or genital herpes. If the child’s lesions were caused by HSV type 2, the suspect’s negative serology for HSV type 2 could possibly exclude him as being the source of the infection, but a positive serology would only mean that he could have been, but not necessarily was, the source. Another complicating factor is the high false positive rate for HerpeSelect-2 EIA (Focus Technologies) testing in populations with a low prevalence of HSV. One study¹⁷ showed that in populations with a low prevalence of HSV type 2 (16% in US adults), the test result would be positive in approximately 50% of individuals, when the confirmatory test (Western blot analysis) was negative. This high false positive rate was one of the reasons that the United States Preventive Services Task Force recommended against serologic testing for HSV in asymptomatic adolescents and adults.¹⁷ HSV serology is also not included in the postsexual assault serologic screening studies recommended by the CDC.⁶

Female Genital Mutilation

One addition to the table is an item listing the findings seen in children as a result of ritual female genital mutilation (FGM) or genital cutting. It might be difficult for medical providers to determine, in young girls, whether part of the clitoris, clitoral hood, labia minora, or labia majora has been pricked, scraped, or removed. In type 4 FGM, a small vertical laceration is made adjacent to the clitoris on one side, leaving a thin scar, which might not be noticed by the examiner. In one study,¹⁸ type 4 was the most common type of FGM detected in the children who were examined.

Notches/Clefts in the Hymen

The 2018 updated table simplifies the categorization of notches and clarifies their significance on the basis of location and depth. There have been no recent studies that have prompted these changes but review of past studies^{19–23} and polling of experts who have contributed to past publications of this table have called for clarification. Some providers use the terms, “notch” and “cleft” interchangeably, whereas others prefer “cleft,” which might be considered a more neutral term. Notches/clefts are either deep, defined as “nearly to the base” of the hymen, or not deep. A notch or cleft is distinct from a transection, which is a defect in the posterior hymen rim that “extends to or through the base of the hymen.”

The finding of a deep notch/cleft in the hymen at or below 3 and 9 o’clock is listed in the “No expert consensus/findings inconclusive for abuse” section of Table 1, because this is a rare finding that has been reported in a few prepubertal²⁰ and pubertal patients²¹ with a history of sexual abuse, or consensual intercourse.²² However, current studies do not show a consistent pattern of whether lacerations of the hymen heal²³ to a transection, a deep notch, or a nonspecific finding. Complete clefts/healed transections

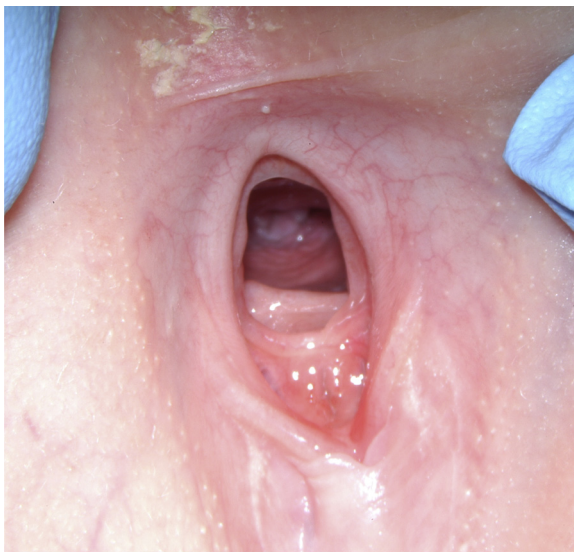

Fig. 5. This is a photograph of the same child as in Figure 4. She has been placed in the prone knee-chest position, kneeling on the examination table with her buttocks elevated, so her anus would be at the top of the photograph. The hymen has a more thinned out appearance, but the edges are smooth, and there are no notches or other signs of past injury. Without magnification, it might appear to an inexperienced clinician that there was no hymen, but it is present around the whole opening. This examination does not show any signs of past injury or abuse.

below 3 and 9 o'clock are considered residual findings caused by trauma and/or sexual contact that are the result of acute hymenal lacerations to or through the base of the hymen.²³

Complete clefts at the 3 or 9 o'clock location are listed separately in the table in the same section. This finding has not been documented in studies of nonabused children,²⁰ but narrowing at 3 and 9 o'clock is not an unusual finding in adolescent girls. Complete clefts at 3 or 9 o'clock have been noted more often in adolescent girls who describe past consensual intercourse (7 of 27; 26%) than in girls who denied past intercourse (3 of 58; 5%; $P < .01$) in one study.²² All notches/clefts that are not deep, as defined previously, are considered normal variants. Notches or clefts, of any depth, above 3 and 9 o'clock, are also considered normal variants.

Photo Documentation

All findings thought to be anything but normal should be documented with high-quality still photos or video imaging. For findings listed in Table 1 sections 1D and 1E, it is recommended that the images be reviewed by an expert in child sexual abuse evaluation to ensure accurate diagnosis.

Conclusion

The main updates to the 2016 guidelines for the medical assessment and care of children who might have been sexually abused² are in the sections discussing examination documentation, testing for STIs, and the interpretation of medical and laboratory findings. A recent survey of physicians with experience in child sexual abuse evaluation indicates that there appears to be 80%–100% agreement with all but 1 of the current interpretations. The finding of a deep notch in the posterior hymen is still an inconclusive finding, with no expert consensus as to the degree of significance with respect to abuse.

There is also new evidence that viewers of video recordings, as opposed to still photos of examination findings, showed significantly greater agreement with the examining clinician as to the diagnosis of a hymen transection.³ These results suggest that videography, as opposed to still photographs, might be a preferred method for documenting findings in cases of child sexual abuse.

When screening for STIs in prepubertal and adolescent girls who present with suspected sexual abuse, NAAT tests on “dirty” urine samples have proved superior to vaginal cultures. This method will likely also be more sensitive in diagnosing *T. vaginalis*, because newer tests are now available. Confirmation testing using an alternate target NAAT remains important for cases in which the result could have forensic significance.

The table listing an approach to the interpretation of medical and laboratory findings in child sexual abuse, published in 2016² has been revised slightly, mainly by

clarifying the description of findings, separating physical findings into acute and nonacute types, and listing laboratory findings separately. It is hoped that the revised table will continue to be useful in helping medical providers to interpret the findings in children examined for signs of sexual abuse.

Acknowledgments

The authors thank Vincent Palusci, MD, Nancy Harper, MD, Rebecca Moles, MD, and Lori Frasier, MD for their reviews and comments on this article.

References

- Gallion HR, Milam LJ, Littrel LL: Genital findings in cases of child sexual abuse: genital vs. vaginal penetration. *J Pediatr Adolesc Gynecol* 2016; 29:604
- Adams JA, Kellogg ND, Farst KJ, et al: Updated guidelines for the medical assessment and care of children who may have been sexually abused. *J Pediatr Adolesc Gynecol* 2016; 29:81
- Killough E, Spector L, Moffatt M, et al: Diagnostic agreement when comparing still and video imaging for the evaluation of child sexual abuse. *Child Abuse Negl* 2016; 52:102
- Leder MR, Leber AL, Marcon MJ, et al: Use of Aptima Combo 2: the experience of a child advocacy center. *J Child Sex Abus* 2013; 22:297
- Jenny C, Crawford-Jakubiak JE: Committee on Child Abuse and Neglect, American Academy of Pediatrics: The evaluation of children in the primary care setting when sexual abuse is suspected. *Pediatrics* 2013; 132:e558
- Centers for Disease Control: Sexually Transmitted Diseases Treatment Guidelines. Available. <https://www.cdc.gov/std/tg2015/default.htm>; 2015. Accessed August 1, 2016.
- Hammerschlag MR, Gaydos CA: Guidelines for the use of molecular biological methods to detect sexually transmitted pathogens in cases of suspected sexual abuse in children. *Methods Mol Biol* 2012; 903:307
- Peters RP, Nijsten N, Mutsaers J, et al: Screening of oropharynx and anorectum increases prevalence of Chlamydia trachomatis and Neisseria gonorrhea infection in female STD clinic visitors. *Sex Transm Dis* 2011; 38:783
- Bachmann LH, Johnson RE, Cheng H, et al: Nucleic acid amplification tests for diagnosis of Neisseria gonorrhea and Chlamydia trachomatis rectal infections. *J Clin Microbiol* 2010; 48:1827
- Kellogg ND, Melville JD, Lukefahr JL, et al: Genital and extragenital gonorrhea and chlamydia in children and adolescents evaluated for sexual abuse. *Pediatr Emerg Care* 2017; <https://doi.org/10.1097/PEC.0000000000001014>. [Epub ahead of print].
- Hobbs MM, Sena AC: Modern diagnosis of Trichomonas vaginalis infection. *Sex Transm Infect* 2013; 89:434
- Van Der Pol B: Clinical and laboratory testing for Trichomonas vaginalis infection. *J Clin Microbiol* 2016; 54:7
- Lee R, Schwartz RA: Pediatric Molluscum contagiosum: reflections on the last challenging poxvirus infection, part 2. *Cutis* 2010; 86:287
- Zichichi L, Maniascalco M: The challenges of a neglected STI: Molluscum contagiosum. *G Ital Dermatol Venerol* 2012; 147:447
- Bacopoulou F, Karakitsos P, Kottaridi C, et al: Genital HPV in children and adolescents: does sexual activity make a difference? *J Pediatr Adolesc Gynecol* 2016; 29:228
- Bernstein DI, Bellamy AB, Hook EW, et al: Epidemiology, clinical presentation, and antibody response to primary infection with herpes simplex virus type 1 and type 2 in young women. *Clin Infect Dis* 2013; 56:344
- Feltner C, Grodensky C, Ebel C, et al: Serologic screening for genital herpes; an updated evidence report and systematic review for the US Preventive Services Task Force. *JAMA* 2016; 316:2531
- Hodes D, Armitage A, Robinson K, et al: Female genital mutilation in children presenting to a London safeguarding clinic: a case series. *Arch Dis Child* 2016; 101:212
- Berkoff MC, Zolotor AJ, Makoroff KL, et al: Has this prepubertal girl been sexually abused? *JAMA* 2008; 300:2779
- Berenson AB, Chacko MR, Wiemann CM, et al: A case-control study of anatomic changes resulting from sexual abuse. *Am J Obstet Gynecol* 2000; 182:820
- Adams J, Knudson S: Genital findings in adolescent girls referred for suspected sexual abuse. *Arch Pediatr Adolesc Med* 1996; 150:850
- Adams JA, Botash AS, Kellogg N: Differences in hymenal morphology between adolescent girls with and without a history of consensual sexual intercourse. *Arch Pediatr Adolesc Med* 2004; 158:280
- McCann J, Miyamoto S, Boyle C, et al: Healing of hymenal injuries in prepubertal and adolescent girls: a descriptive study. *Pediatrics* 2007; 119:e1094